

Toxicological Effect Of Polyvinyl Chloride on Reproductive System of Albino Rats

El-Shawarby, R.M. and Nabila, M. Abdel-Alim

Dept. of Forensic Med. and Toxicology

Faculty of Vet. Med. Zagazig University, Benha Branch

ABSTRACT

Effect of polyvinyl chloride on reproductive system of male and female rats were studied. Polyvinyl chloride was given orally at 5 ppm dose level (Threshold limit value, Egyptian Environmental law 1994) to pregnant female rats daily from 6th-15th day of pregnancy and a second group was kept as control. PVC was also administered with same dose to male albino rats three times/week for two months. Pregnant female rats were sacrificed on 20th gestation day. There was reduction in number of fetuses, fetal viability, fetal weight and fetal length. Enlarged liver and hypoplasia of brain were the only visceral abnormalities detected. Skeletal development appeared similar to that of control animals except absence of coccyal vertebra in one case. Seminal changes recorded were decrease in sperm cell concentration and individual movement percent, in addition to increase of total sperm abnormalities percentage. Histopathological examination of reproductive organs revealed congestion of blood vessel, deposition of haemosiderin pigment in uterus and ovary, degeneration of some ovarian follicle. Edema of testis, destruction of sperm and eosinophilic mass in seminiferous tubules were also detected.

INTRODUCTION

Polymer materials are incriminated in furniture, clothing, packaging systems and may be parts of tissue and organ implanted into man to save or prolong life. The expanding use of all types of man made materials has underlined the importance of toxic potential of these compounds. Polyvinyl chloride (PVC) is a very durable, practical and economical plastic, which is so wide spread in its use that it may become difficult to replace it. The annual amount of world production has been constantly increasing. While PVC is so useful, the health hazards which accompany this plastic are causing alarm in the industrially countries. Polyvinyl chloride caused angiosarcoma of the liver, Acro-osteolysis of the fingers and sclerodermic type skin lesions (1). Oral administration of polyvinyl chloride caused marked hyperplasia of gastroduodenal mucosa; with polypoid figures activation of pulmonary interstitial tissue and subcutaneous histiocytic lymphoma in rats (2). Three patients with industrial exposure to PVC developed angiosarcomas of the liver. One patient has multi-lobular primary hepatocellular carcinoma (3).

Rats inhaled polyvinyl chloride dust at concentration of 10 mg/m³ for 6 hr/day, 5 days/week for 15 weeks showed scattered lung lesions (4). Polyvinyl chloride (PVC) used in processing of certain tubes used in medical practice administration devices, catheters, part of dialysis devices and plastic bottles for packaging of liquids. Possible toxic interaction between food and PVC container can occur

(5). The same author added that human exposed to vinyl chloride in air at a concentration of 6000 ppm for half an hour showed dizziness and drowsiness. Mean pH of platelet storage in polyvinyl chloride container was dropped from 7.23 on day 0 to 6.68 by day 5 (6). 253 cases of death were recorded in seven plants used polyvinyl chloride. Where information from death certificate indicated that 14 cases had liver cancer; and seven with angiosarcoma and two with hepatocellular carcinoma (7). Single intratracheal instillation of 25 mg/rat polyvinyl chloride caused increase in total organ fresh weight, dry weight, DNA, RNA and protein content (8). Polyvinyl chloride has carcinogenic action on the liver (9); and oliguric renal failure (10). Acute toxicity may occur due to product of conveyor tap burning "Tape used in coal mines and processed from polyvinyl chloride" (11). Growth of human umbilical endothelial cells cultured on soft polyvinyl chloride plastics plate was significantly less than that on the control plate (polystyrene cell culture plates) with the same coated substance. Tissue plasminogen activator from cell cultured on PVC was up to four times than control cells (12). Incidence of seminoma and embryonal testicular cancer were increased, in exposure to polyvinyl chloride than other types of plastics (13). Vinyl chloride affected two genotypes, CYP2 E1 and GSTT1, which may play important roles in the biotransformation of vinyl chloride (14). Platelets stored in polyvinyl chloride bag showed increase CO₂ tension and low in O₂ tension (15). Women's come contact with common estrogenic

compounds as detergents, plastics and polychlorinated biphenyls should be limited (16). American conference of Government Industrial Hygienists recorded that threshold limit value (TLV) of vinyl chloride is 1 ppm, while Egyptian environmental law (law No. 4, 1994) recorded that maximum permissible limit is 5 ppm.

The purpose in the present study was to give an idea about the possible teratogenic effect of polyvinyl chloride on female albino rats and on semen quality of male albino rats.

MATERIALS AND METHODS

A: Chemicals :

Polyvinyl chloride is white fine crystals obtained from "BDH laboratory supplies, Poole, Dorset, England ".The chemical unit structures of polyvinyl Chloride is $\{-CH_2-CHCl-\}$.

B: Experimental design :

Effect on pregnant females: This study was carried out on twenty mature female albino rats weighing 180-200g. Daily vaginal smears were examined for detection of female in oestrus. Female in oestrus was left with male over night and a vaginal smear was examined to detect zero day of pregnancy. Two equal groups of pregnant female each of 10 were used. The first group kept as non treated control group. The second was given polyvinyl chloride at dose level of 5 ppm which was equal to threshold limit values according to Egyptian Environmental law for 1994. The studied substance was given daily in corn oil by metallic stomach tube from 6th to 15th day of gestation. During this period, the different organs developed and become more sensitive to the effect of tested material (17). Both control and treated pregnant females were kept under observation until the 20th day of gestation at which they were sacrificed by decapitation and dissected to examine the effect of polyvinyl chloride on fetal development. The uterus and uterine horns were examined carefully for resorption sites, foeti from each mother were examined morphologically by counted and separated to dead and live foeti. Each foetus was dried on absorbent paper, where weight and crown rump length (CVR) were recorded and examined for external malformation. Some of

the foeti were fixed in Bouin's solution for at least one week for examining visceral abnormalities (18). Other foeti were eviscerated and kept in 95% ethanol for one week then cleared with 2% KOH for 24-32 hours. Then the foeti were immersed in Mallsch's solution with alizerin red for 24 h. (19). The stained foetuses were kept in Mallsch's solution alone for 2 days, then rinsed in cold water and cleared by successive passage in graded concentration of glycerol in 2% potassium hydroxide solution. The stained skeleton was examined under the stereo microscope for skeletal malformations.

Effect on male rats: Twenty mature male albino rats were divided into two equal groups each of 10 rats. First group kept as a control. Second group given three time weekly polyvinyl chloride in corn oil at concentration of 5ppm (TLV according to Egyptian Environmental law, 1994) by stomach tube for two months. Animals were sacrificed and sera were obtained for estimation of testosterone by direct radioimmuno assay (20) and the testis were desiccated. Semen samples were obtained by cutting the tail of epididymis and crushed it gently in clean petri dish which contained 2 ml normal saline solution. Semen was evaluated (21).

Pathological examination

Specimens from intestine, uterus, placenta, ovary and testis were processed for routine histopathological examination. Statistical analysis of our data were performed by t -test using steatase program (22).

RESULTS

Table (1) shows morphology of foetuses obtained from female pregnant rats administered orally 5 ppm of polyvinyl chloride from the 6th to 15th day of gestation in comparison to foetuses from non-treated mother. Percentage of viable foetuses from female pregnant rats was 78.6%, while that of dead fetuses was 21.4%. Twenty two resorbed foetuses were recorded in polyvinyl chloride treated rats while control group showed no fetal resorption (Table 1, Fig.1). A significant decrease was recorded in both foetal weight and crown rump length (Fig.2). The mean values of foetal body weight and crown-rump length were 2.8 ± 0.29 and 3.4 ± 0.14 cm while

those from control group were 5 ± 0.11 and 4.8 ± 0.34 cm (Table 1).

Table (1): Effect of Polyvinyl chloride on morphology of fetuses obtained from mother given 5 ppm of PVC from 6th to 15th day of pregnancy.

Parameters	Control group	Group given 5ppm polyvinyl chloride
Number of female rats	10	10
No. of viable fetuses	65	33
Viable fetuses %	100%	78.6%
No. of dead fetuses	-	9
Dead fetuses %	-	21.4%
No. of resorped fetuses	-	22
Fetal body weight (g)	5 ± 0.11	$2.8^{**} \pm 0.2$
Fetal crown-rump lengths (cm.)	4.8 ± 0.31	$3.4^{**} \pm 0.41$

* Significant at $P < 0.05$

**Significant at $P < 0.01$

Visceral examination of living fetuses obtained from mothers given 5 ppm oral dose of polyvinyl chloride from 6th to 15th day of gestation revealed some visceral abnormalities such as liver enlargement (Fig.3) in 26.6% (Four cases from 15 examined fetus). Hypoplasia of brain was detected in one case (Fig.4). Examination of skeleton of fetuses obtained from dams given 5ppm polyvinyl chloride from 6th to 15th day of pregnancy showed absence of caudal vertebrae only in one case from examined fetuses as clear in Fig.5.

Table (2) shows non significant changes in weights of right or left testis from male albino rats administered 5 ppm polyvinyl chloride orally. Highly significant decrease in sperm cell concentration was detected in male Albino rats administered orally 5ppm polyvinyl chloride for two months. Sperm cell concentrations were $160.6 \pm 3.33 \times 10^6$ ml for treated group in comparison to $240.6 \pm 6.6 \times 10^6$ ml for control group. Administration of 5ppm polyvinyl chloride to male albino rats induced a significant increase in total sperm abnormalities percentage and individual movement.

Total sperm abnormalities and individual movement percentages were $8.33 \pm 33.3\%$ and $45 \pm 2.3\%$ respectively in comparison to 1.66 ± 1.2 and $73 \pm 5.2\%$ for control group. Testosterone level decreased to 2.1 ± 0.06 while that of control was 3.6 ± 0.1 ng/ml of control group.

Table (2): Seminal changes of male albino rats after oral administration of 5ppm of polyvinyl chloride for two months (Mean \pm S.E.).

Parameters	Control group	Group (administered orally 5ppm PVC)
Weight of right tests	1.53 ± 0.08	1.4 ± 0.05
Weight of left tests	0.8 ± 0.03	0.7 ± 0.05
Total sperm cell conc. $\times 10^6$ ml	240.6 ± 9.6	$160.6^{**} \pm 13.33$
Total sperm abnormalities %	1.66 ± 1.2	$8.33^{*} \pm 33.3$
Individual movement %	73 ± 1.52	$45^{**} \pm 2.3$
Testosterone (ng/ml)	3.6 ± 0.1	$2.1^{**} \pm 0.06$

* Significant at $P < 0.05$

**Significant at $P < 0.01$

Pathological finding

Uterus: Microscopic examination of uterus revealed congestion of blood vessels with focal desquamation of endometrial epithelial cells. In addition, focal deposition of golden yellow granules of haemosiderin pigment were prevalent (Fig.6 and 7). Mononuclear inflammatory cellular infiltration of endometrium was also detected.

Ovary: Congestion of blood vessels with inflammatory cellular infiltration of ovarian tissues were seen. Degeneration of some ovarian follicles was also observed (Fig.8). Perivascular edema and multiple areas of haemosiderosis were also detected.

Placenta : Congestion of placental blood vessels with hyperplasia of lining epithelium were detected. Homogenous eosinophilic necrotic tissue was seen (Fig.9). Moreover, focal areas of edema were also recorded.

Intestine: Congestion of submucosal blood vessels with mononuclear cellular infiltration of lamina propria and submucosa were found. Focal hyperplasia of lining epithelium of intestinal mucosa was recorded

(Fig.10). Moreover cellular debris within lumen of intestine was found in some examined cases.

Testis : Histopathological examination of testis showed congestion of blood vessel and odema of intertubular tissue. Moreover, destruction and necrosis of sperms with presence of homogenous eosinophilic mass structures within some seminiferous tubules were also recorded (Fig.11).



Fig (1): Resorbed foeti in the uterus from dam administered polyvinyl chloride.

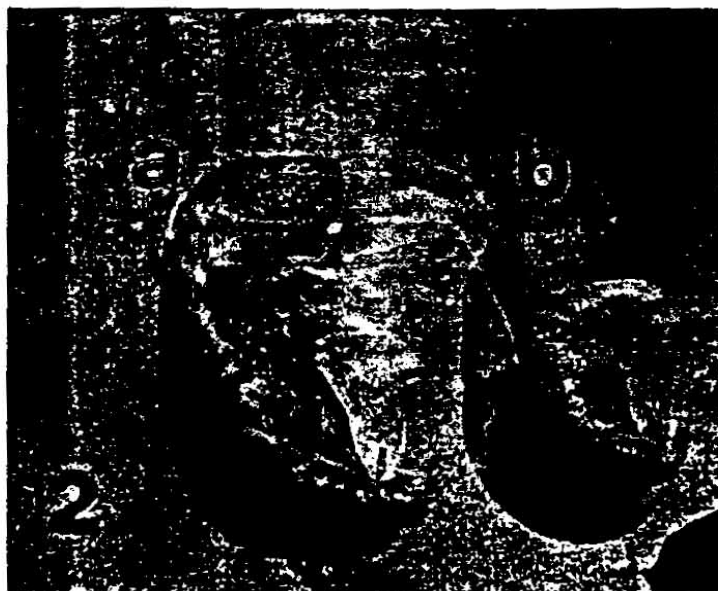

Fig (2): Stunted growth foetus from treated dam (A) and foetus from normal group.




Fig. (3): Enlarged liver of foetus from treated dam (A) and normal liver (B).




Fig. (4): Hypoplasia in brain of foetus from treated dam (A) and normal brain (B).




Fig. (5): Absence of caudal vertebra in foetus from treated dam (A) and normal foetus (B).




Fig. (6 and 7): Uterus of female albino rats administered 5 ppm PVC showed congestion of blood vessel, focal desquamation of endometrial epithelial cells and focal deposition of haemosiderin pigment (H&E) X 200.




Fig. (8): Ovary showed congestion of blood vessel and inflammatory cellular infiltration and degeneration of some ovarian follicles (H&E) X 400.




Fig. (9): Placenta showed congestion of blood vessel, hyperplasia of lining epithelium and homogenous eosinophilic necrotic tissue(H&E) X 400.



Fig. (10): Intestine showed mononuclear cellular infiltration of lamina propria, focal hyperplasia of lining epithelium (H&E) X 400.

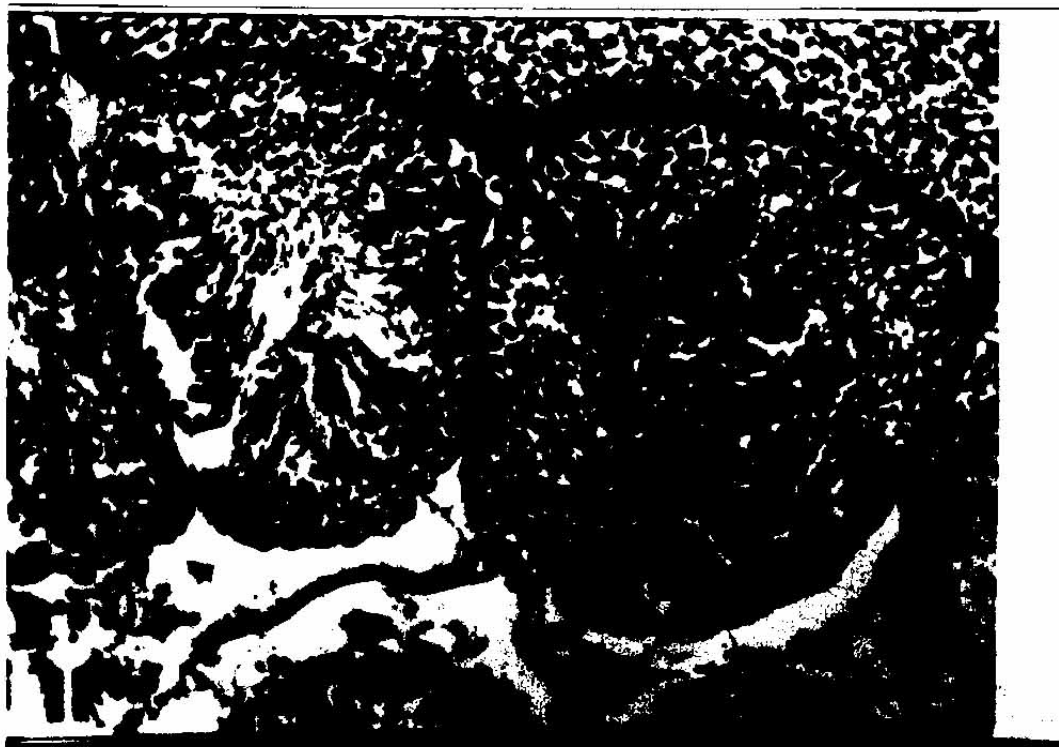

Fig. (11): Testes of male albino rat showed destruction and necrosis of sperms and homogenous eosinophilic mass within seminiferous tubules (H&E) X 400.

DISCUSSION

In the present work effect of 5 ppm polyvinyl chloride was detected on female and male reproductive efficiency. From our results 5ppm polyvinyl chloride had a teratogenic effect on rats; which clarified by resorbed and dead foetuses, decrease in fetal weight and length; liver enlargement; brain hypoplasia and finally absences of caudal vertebrae. These observation were not previously recorded but polyvinyl chloride has an effect on DNA and RNA of rat (8); decreased the growth of human umbilical endothelial cell (12) and affected two genotypes that may play a role in PVC biotransformation and one of estrogenic compound (16). This result is confirmed by pathological findings of uterus, ovary and placenta.

Effects of polyvinyl chloride on fertility of male rats was pronounced and manifested by reduction in sperm cell concentration, percentage of individual motility and increase in total sperm abnormality in addition to decrease in level of testosterone. These results may be attributed to the effects of vinyl chloride on fertility (13). The outhers (13) recorded an increased incidence of seminoma and embryonal testicular cancer in exposure to polyvinyl chloride than other plastics infertility action was confirmed by pathological finding of the testis.

The available literature did not provide sufficient information about pathological changes of reproductive organs associated with administration of PVC. However the present study revealed that polyvinyl chloride caused some changes in the form of congestion of blood vessels, cellular infiltration, edema, necrosis and degeneration of some ovarian follicles. These alterations may be returned to toxic effect of hydrochloric acid, carbon monoxide and phosgene that released from decomposition of polyvinyl chloride (23). Testicular changes recorded in our result in form of edema destruction and necrosis of sperm are in agreement with a previously cited record (13), who recorded seminoma and embryonal testicular cancer in workers exposed to polyvinyl chloride. These results may be due to similar effect as mentioned previously in female reproductive organs.

that harmful effects

of new man-made materials as plastics are much more prevalent than originally suspected.

REFERENCES

- 1- Sadick, A. (1976) : Special communication polyvinyl chloride vinyl chloride disease, and occupational health hazard. JPMA. J. pak. Med. Assoc. 26 (2) p. 37-39.
- 2- Faa, G.; Dessy, E.; Bucavelli, A.; Frau, G.; Zucca, G and Draetta, G. (1981): Experimental research on the toxicity of PVC administered orally. Boll. soc. Ital. Biol. Sper. 57 (8) P. 926-928.
- 3- Koischwitz, D.; Lebach, W. K., Lackner, K. and Hermanutz, D. (1981): Vinyl chloride-induced angiosarcoma and hepato-cellular carcinoma of the liver. Rofo fortschr. Geb. Röntgenstr. Nuklearmed. 134(3) p. 283-290.
- 4- Richards, R.J.; Cobbl, M.; Hardy, C.J.; Rose, F.A.; Tetley, T. D. (1981): Effect on rat of inhaling PVC dust at the nuisance dust level (10mg/m³) Arch. Environ. Health, 36:1, 4-9.
- 5- Johon, A. (1980): Casartie and Doull's: The basic science of poisons "Plastics" Chapter' 20 P.533 2nd Ed. Edited by Doull, J., Klaassen, C.D. and Amdur, M. O. Macmillan publishing Co Inc. New York.
- 6- Gorde, G.; Miripol, J.; Barber, T. and Buchholz, D. H. (1985): Extended storage of platelets in a new plastic container. I. Biochemical and morphologic changes. Transfusion. 25:3, 204-8.
- 7- Pirastu, R.; Comba, P. Reggiani, A.; Foa, V.; Masina, A. and Maltoni, C. (1990): Mortality from liver disease among Italian vinyl chloride monomer/ polyvinyl chloride manufactures. Am. J. Ind. Med., 17 (2): 155-161.
- 8- Agarwal, D. K.; Dogra, R. K. and Shanker, R. (1991): Pathobiochemical response of tracheobronchial lymph nodes following intratracheal instillation of polyvinyl chloride dust in rats. Arch. Toxicol. 65:6, 510-517.
- 9- Pirastu, R. Belli, S.; Bruno, C.; Comba, P.; Desantis, M.; Foa, V.; Maltomi, C.; Masina, A. and Reggiani, A. (1991): The mortality among the markers of vinyl

- chloride in Italy. *Med. Lar.* 82:5, 388-423.
- 10- *Riordan, S. M.; Loo, K.; Harber, R. W.; Thomas, M. C. (1991):* Vinyl chloride related hepatic angiosarcoma in a polyvinyl chloride autoclave cleaner in Australia. *Med. J. Aust.* 15, 155 (2): 125-128.
- 11- *Bolonova, L.N.; Sukhanov, V.V. and Teplova, T. E. (1996):* Toxicity of chemicals produced by thermal destruction of synthetic materials based on polyvinyl chloride and used in coal mines. *Med. Tr. prom E. Kol.* 2:24-27.
- 12- *Storck, J.; Delrazek, A. and Zimmermann, E. R. (1996):* Effect of polyvinyl chloride plastic on the growth and physiology of human umbilical vein endothelial cells. *Biomaterials*, 17: (18) 1791-1794.
- 13- *Hardell, L.; Ohlson, C. G. and Fredrikson, M. (1997):* Occupational exposure to polyvinyl chloride as a risk factor for testicular cancer evaluated in a case-control study. *Int. J. Cancer*, 73:6, 828-830.
- 14- *Huang, C. Y.; Huang, K. L.; Chenge, T. J.; Wang, J. D. and Hsieh, L.L. (1997):* The GSTT and CYP2E, genotypes are possible factors causing vinyl chloride induced abnormal liver function. *Arch. Toxicol.* 71:(8), 482-488.
- 15- *Krishnan, L. K.; Mathai, J.; Sulochana, P.V.; Jacob, J. and Sivakumar, R. (1997):* Biochemical lesions of platelets stored as concentrates in PVC bags. *Indian J. Med. REs.*, 105:85-92.
- 16- *Steintgaber, S. (1997):* Mechanisms proof unmet needs: The perspective of a cancer activist. *Environ Health prospect*, 05 (3) 685-687.
- 17- *Tuchmann-Duplessis, H. (1985):* Drug effects on the feets. ADIS press, New, York, USA.
- 18- *Hayes, A. W. (1986):* Principles and methods of toxicology Raven press, New York, U.S.A.
- 19- *Staples, R. E. and Schnell, V. L. (1964):* Refinements in rapid clearing technic in the KOH-Alizerin red method for foetal bone stain technology. 39: 61-63.
- 20- *Yalow, R., Berson, S. (1971):* Introduction and general considerations, In: odellwd, Doughaday W. H. (eds): Principles of competitive protein binding assays. J. B. Lippin cott. Philadelphia, PP. 1-19.
- 21- *Bearden, H. J. and Fluquary, J. (1980):* "Applied Animal Reproduction" Reston published Co., Inc. Reston, Virginia, P. 158-160.
- 22- *Data plus systems, Inc.(C) (1986):* Statease programe.
- 23- *Ropert, H. and Dreis, B. A. (1983):* Hand book of poisoning prevention, diagnosis and treatment. 11 Edition p. 220.